


ORIGINAL ARTICLE

Open Access



# Evaluation of retinal structural and functional changes after silicone oil removal in patients with rhegmatogenous retinal detachment: a retrospective study

Ran Dou<sup>1</sup>, Rui Li<sup>2</sup>, Rui-chan Li<sup>2</sup>, Yan-ru Yu<sup>2</sup>, Jin-xiu Zhou<sup>2</sup>, Rui-mei Li<sup>2</sup>, Xia-ping Wang<sup>2</sup>, Dong-chang Zhang<sup>2</sup>, Jian Jiang<sup>1\*</sup>  and Song Chen<sup>3\*</sup>

## Abstract

**Background** To evaluate retinal structural and functional changes after silicone oil (SO) removal in eyes with macula-off rhegmatogenous retinal detachment (RRD).

**Methods** Best-corrected visual acuity (BCVA) testing, microperimetry, and optical coherence tomography angiography were performed in 48 eyes with macula-off RRD before and 3 months after SO removal. The values of healthy contralateral eyes were used as control data. Correlations between retinal vessel density (VD), retinal nerve fiber layer thickness (RNFLT), the interval between retinal detachment and surgery, the duration of SO tamponade, the follow-up time after SO removal, and visual function were analyzed.

**Results** Significant increases in 2° fixation rate (FR), 4° FR, 2° mean retinal sensitivity (MRS), 6° MRS, parafoveal superficial capillary plexus VD and RNFLT were observed after SO removal (all  $P < 0.05$ ). The increase of 2° MRS and 6° MRS were correlated with the duration of SO tamponade and the follow-up time after SO removal respectively (all  $P < 0.05$ ). The last 2° MRS and 6° MRS were correlated with the duration of SO tamponade, the interval between retinal detachment and surgery, and the follow-up time after SO removal (all  $P < 0.01$ ). The last FR in RRD eyes was close to that of contralateral eyes ( $P > 0.05$ ).

**Conclusion** Retinal structure and function improved to different degrees after SO removal. Fixation stability and retinal sensitivity increased more than BCVA postoperatively. Retinal sensitivity, which was affected by the interval between retinal detachment and surgery and the duration of SO tamponade, gradually recovered after SO removal.

**Keywords** Microcirculation, Microperimetry, Optical coherence tomography angiography, Rhegmatogenous retinal detachment, Silicone oil

\*Correspondence:

Jian Jiang  
[thisisjiangjian@126.com](mailto:thisisjiangjian@126.com)

Song Chen  
[chensong9999@126.com](mailto:chensong9999@126.com)

Full list of author information is available at the end of the article



© The Author(s) 2023. **Open Access** This article is licensed under a Creative Commons Attribution 4.0 International License, which permits use, sharing, adaptation, distribution and reproduction in any medium or format, as long as you give appropriate credit to the original author(s) and the source, provide a link to the Creative Commons licence, and indicate if changes were made. The images or other third party material in this article are included in the article's Creative Commons licence, unless indicated otherwise in a credit line to the material. If material is not included in the article's Creative Commons licence and your intended use is not permitted by statutory regulation or exceeds the permitted use, you will need to obtain permission directly from the copyright holder. To view a copy of this licence, visit <http://creativecommons.org/licenses/by/4.0/>. The Creative Commons Public Domain Dedication waiver (<http://creativecommons.org/publicdomain/zero/1.0/>) applies to the data made available in this article, unless otherwise stated in a credit line to the data.

## Background

Silicone oil (SO) -related vision loss (SORVL) is a side effect of SO which is frequently utilized in rhegmatogenous retinal detachment (RRD). Best corrected visual acuity (BCVA) is not the only assessment used to evaluate postoperative visual function. Unlike the BCVA test, which depends on the ability to distinguish spatial patterns, retinal sensitivity tested using microperimetry is based on the ability to discriminate low-contrast signals [1]. Few studies have investigated the effect of SO tamponade on retinal sensitivity. Previous studies have shown that retinal sensitivity decreased after SO tamponade and increased after SO removal in RRD eyes [2, 3]. However, the underlying mechanisms remain unclear. Our previous studies showed that SO tamponade could result in a decrease in macular and peripapillary capillary vessel density (VD) and retinal nerve fiber layer thickness (RNFLT) [4, 5]. Whether the effect of SO on retinal sensitivity is correlated with VD and RNFLT remains unclear.

This study aimed to evaluate retinal structural and functional changes in RRD eyes before and 3 months after SO removal using microperimetry and optical coherence tomography angiography (OCTA), to analyze related correlation.

## Methods

This retrospective study was performed in accordance with the tenets of the Declaration of Helsinki and was approved by the ethics committee. Unilateral RRD eyes successfully repaired using pars plana vitrectomy (PPV) with SO tamponade were followed-up for more than 3 months after simple SO removal surgery from January 2020 to December 2021. All participants underwent examinations before and 1 week, 2 weeks, 1 month, 3 months, and 6 months after SO removal, including BCVA, intraocular pressure (IOP), slit-lamp biomicroscopy examination, fundus examination. OCTA and microperimetry were performed once more than 3 months after SO removal.

The exclusion criteria were as follows: (1) age < 18 years; (2) prior ocular surgery; (3) additional ocular diseases (e.g., glaucoma, uveitis, retinal vascular disease, optic disc abnormalities, or macular diseases in either eye); (4) postoperative complications (e.g., endophthalmitis, vitreous hemorrhage, or retinal redetachment); (5) axial length  $\geq 26.5$  mm, or an axial length difference of  $>0.3$  mm between both eyes; (6) any medical condition that could affect the hemodynamics of the eye (e.g., hypertension, diabetes, or Alzheimer's disease); and (7) refractive medium opacity.

Simple SO (Oxane 5700, Bausch & Lomb, Rochester, NY, USA) removal surgery was performed by the same

surgeon using the Alcon Constellation system (Alcon, Fort Worth, TX, USA). Internal limiting membrane (ILM) peeling, scleral buckling, and perfluorocarbon use were avoided in all patients during both surgeries. Fluid-air exchange was applied to reduce the number of emulsified SO droplets. The scleral incisions were sutured using 8-0 absorbable sutures. Phacoemulsification and implantation of foldable intraocular lenses were performed (when required) prior to PPV or SO removal during both surgeries. Approximately 4-mm was removed from the central part of the posterior capsule to prevent opacification.

OCTA was performed to evaluate the parafoveal VD using the RTVue XR Avanti AngioVue system (Optovue Inc, Fremont, CA, USA) with AngioVue OCTA software (version 2018.1.0.43). Relative data were obtained using a split-spectrum amplitude-decorrelation angiography algorithm. A three-dimensional projection artifact removal technique was applied to improve the accuracy of the data. The definitions of the parafoveal region, superficial capillary plexus (SCP) VD, and deep capillary plexus (DCP) VD were consistent with those in the literature [4]. The parafoveal SCP VD, DCP VD, RNFLT, foveal macular thickness (FMT), and foveal avascular zone (FAZ) were automatically generated (Fig. 1).

Microperimetry assessment was performed to evaluate the fixation rate (FR) and mean retinal sensitivity (MRS) using microperimeter-3 (MP-3) (Nidek, Aichi, Japan) in a dimly lit room. Two experienced operators performed the examination. All patients had a pupil size  $>4$  mm in diameter. The MP-3 measurement was carried out using a 4-2 staircase strategy with a Goldmann III stimulus size. The 45 test points were measured accordingly. The maximum luminance of MP-3 was 10,000 asb and the stimulus dynamic ranged from 0 to 34 dB. The fixation target was a 1°-diameter red circle, and the background luminance was set at 31.4 asb. Only reliable visual functions, defined as those with  $<15\%$  false positives and false negatives, were used in the analyses. Using the obtained retinal sensitivities, 2° MRS, 6° MRS, superior 6° MRS, and inferior 6° MRS were calculated. 2° FR and 4° FR were automatically generated (Fig. 2). The same variables in the healthy contralateral eyes were used as control data.

## Statistical analysis

All results were analyzed using SPSS 20.0 for Windows (SPSS, Chicago, IL, USA) software. BCVA was converted to the logarithm of the minimum angle of resolution units. Differences between pre- and post-operative values and between the RRD and healthy contralateral eyes were compared using a Wilcoxon signed-rank test. Correlations were evaluated using a Spearman test. Statistical significance was set at  $P < 0.05$ .

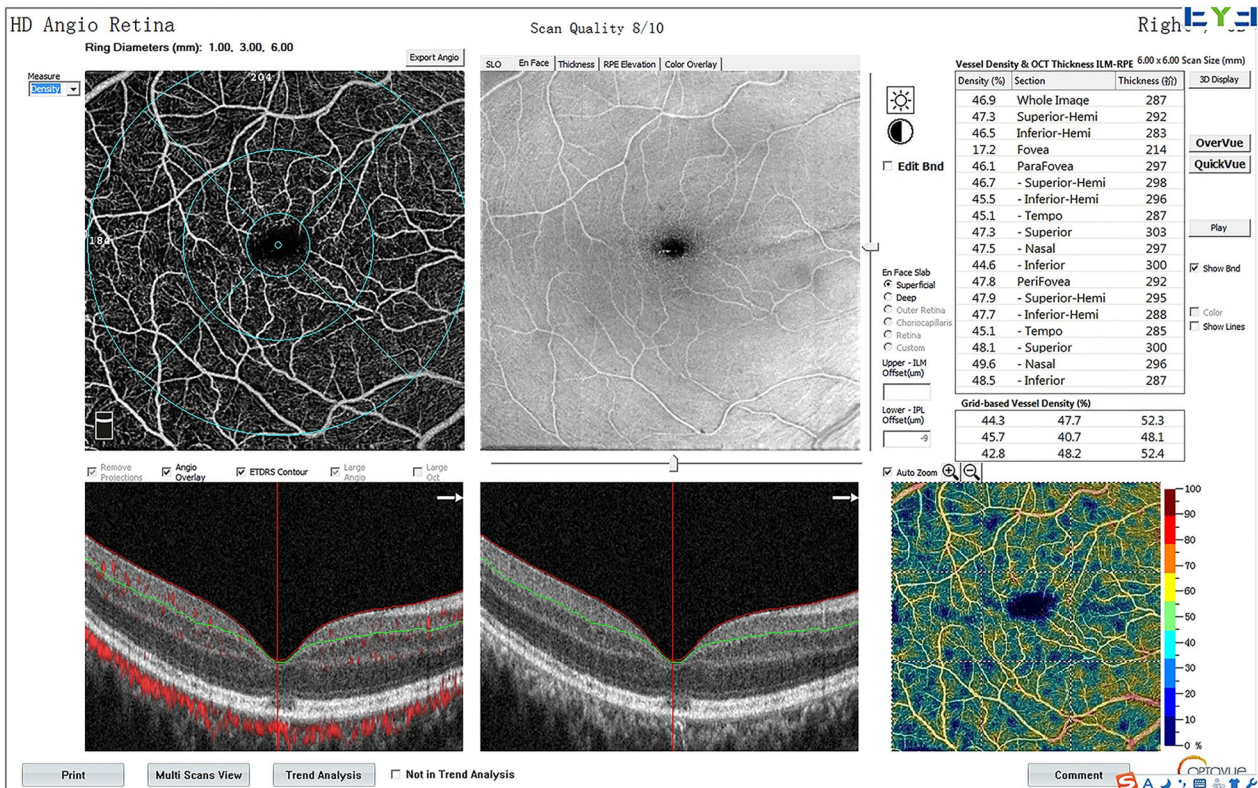


Fig. 1 Example of OCTA image automatically generated showing superficial enface scan, B-scan, and values of vessel density and thickness

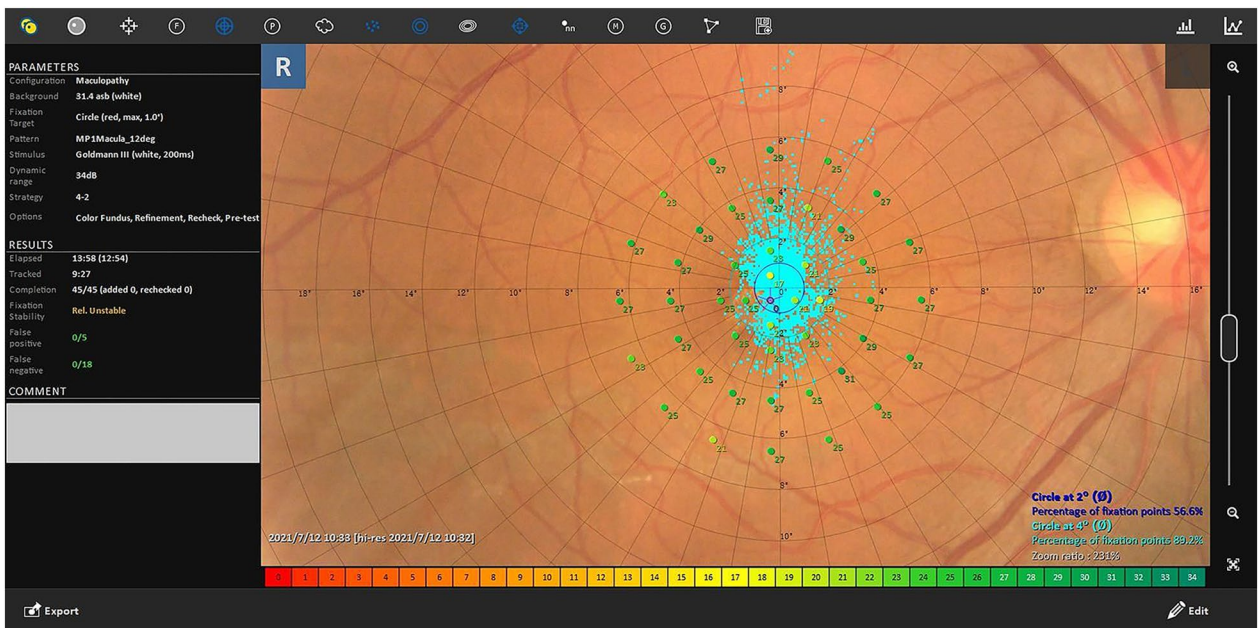


Fig. 2 Example of microperimetry assessment image automatically generated showing retinal sensitivity of each point, 2° fixation rate and 4° fixation rate

**Table 1** Demographics and baseline characteristics of the included patients (n = 48)

Variable	Value (with range)
Mean age (years)	51.9 ± 13.4 (22–75)
Sex (male/female)	22/26
RRD eye (right/left)	29/19
The interval between retinal detachment and surgery (days)	17.4 ± 15.2 (3–75)
Mean duration of SO tamponade (months)	4.4 ± 1.2 (3–7)
Mean follow-up period (months)	4.2 ± 1.1 (3–6)

RRD rhegmatogenous retinal detachment, SO silicone oil

**Table 2** Provides the preoperative and postoperative values of RRD eyes

Variable	Pre-operation	Post-operation	contralateral eye
BCVA (log)	0.67 ± 0.48	0.56 ± 0.50	0.00
2°FR (%)	72.23 ± 20.90	79.25 ± 19.06	83.63 ± 11.15
4°FR (%)	91.65 ± 11.45	94.65 ± 9.01	96.98 ± 3.02
2°MRS (dB)	19.85 ± 5.41	23.27 ± 3.64	26.33 ± 3.28
6°MRS (dB)	22.23 ± 4.27	24.75 ± 3.40	27.13 ± 2.62
Parafoveal SCP VD (%)	42.65 ± 5.46	44.96 ± 5.66	48.98 ± 5.46
Parafoveal DCP VD (%)	48.79 ± 5.02	49.83 ± 4.55	51.50 ± 5.62
Parafoveal RNFLT (µm)	299.42 ± 34.19	309.65 ± 24.27	333.65 ± 48.45
FMT (µm)	248.62 ± 59.54	244.85 ± 28.10	266.91 ± 55.94
FAZ (mm <sup>2</sup> )	0.32 ± 0.11	0.29 ± 0.09	0.29 ± 0.10

BCVA best-corrected visual acuity, FR fixation rate, MRS mean retinal sensitivity, SCP superficial capillary plexus, VD vessel density, DCP deep capillary plexus, RNFLT retinal nerve fiber layer thickness, FMT foveal macular thickness, FAZ foveal avascular zone

## Results

Table 1 shows the baseline demographics and clinical characteristics of the 48 study patients. Phacoemulsification and foldable IOL implantation were performed in 13 eyes during PPV with SO tamponade surgery and 10 eyes during SO removal surgery. The duration of all SO removal surgeries was less than 60 min. A transient increase or decrease in IOP occurred within 1 month after SO removal surgery, after which IOP returned to normal. The increase in IOP was controlled with topical antiglaucoma medication.

2°MRS, 6° MRS, 2° FR, 4° FR, parafoveal SCP VD, and RNFLT increased in RRD eyes after SO removal (all  $P < 0.05$ ). There was no significant difference in BCVA, parafoveal DCP VD, FMT, and FAZ in RRD eyes between before and after SO removal (all  $P > 0.05$ ) (Table 2). BCVA, 2° MRS, 6° MRS, FMT, parafoveal SCP VD, and RNFLT remained lower than those in contralateral eyes after SO removal (all  $P < 0.05$ ).

2° MRS and 6° MRS were correlated with the duration of SO tamponade and the interval between retinal detachment and surgery before SO removal (Table 3). 2°MRS and 6°MRS were correlated with the duration of SO tamponade, the interval between retinal detachment and surgery and the follow-up time after SO removal (Table 4). The increase in 6° MRS was correlated with that in 2° FR, 4° FR, and 2° MRS. The increase in 2° MRS was correlated with the duration of SO tamponade. The increase in 6° MRS was correlated with the follow-up time after SO removal (Table 5).

## Discussion

Microperimetry, which has been applied in many ophthalmic disorders [6–10], can provide MRS and FR measurements for retinal function assessment. Fixation stability, which is usually a key evaluation indicator for macular hole [11], has rarely been used to evaluate visual function after RRD repair. In contrast to BCVA and MRS, there was no significant difference in 2° FR and 4° FR 3 months after SO removal between RRD and healthy contralateral eyes. Rossetti et al. [12] reported that fixation stability in macula-off RRD eyes repaired with scleral buckling recovered well after long-term follow-up. Borowicz et al. [13] evaluated retinal function in eyes with macula-on and macula-off RRD using microperimetry and found that fixation stability recovered relatively well postoperatively. Therefore, we cautiously consider that fixation stability is less affected than BCVA and MRS after experiencing macular detachment and SO tamponade.

Noda et al. [14] reported that post-operative MRS was significantly higher than pre-operative MRS in macula-off RRD eyes, and that post-operative MRS was lower in patients with pre-operative macular detachment. Borowicz et al. [13] reported a significant increase in MRS over time in eyes with macula-on and macula-off RRD after PPV and gas tamponade, and lower MRS in macula-off RRD eyes than in macula-on RRD eyes after surgery. In this study, 2° MRS and 6° MRS remained lower in RRD eyes than in healthy eyes more than 3 months after SO removal. Therefore, we suspect that detached macula may result in damage to retinal sensitivity, which is too severe to ultimately recover from.

Studies concerning the side-effects of SO have been widely reported, among which SORVL has been shown to be independent of the surgeon and the surgical procedure [2, 15, 16]. However, few studies have investigated the side-effects on retinal sensitivity and fixation stability. Several efforts were made to limit surgical factors in this study. First, the intraoperative IOP was controlled at 25 mmHg using the Alcon Constellation system. Second, simple SO removal surgery was performed in all the

**Table 3** Correlation analysis between values before silicone oil removal (Spearman method)

	Duration	Follow-up time	Detachment time	BCVA (logMAR)	2°FR	4°FR	2°MRS	6°MRS	SCPVD	DCPVD	RNFLT	FMT	FAZ
Duration	1.000												
Follow-up time	-0.330*	1.000											
Detachment time	0.660**	-0.520**	1.000										
BCVA	0.320*	-0.183	0.210	1.000									
2°FR	-0.070	-0.089	0.041	-0.093	1.000								
4°FR	-0.033	-0.062	0.051	-0.162	0.950**	1.000							
2°MRS	-0.690**	0.290*	-0.447**	-0.448**	0.092	0.058	1.000						
6°MRS	-0.764**	0.281	-0.517**	-0.436**	0.119	0.113	0.884**	1.000					
SCPVD	-0.242	0.033	-0.120	-0.083	-0.041	-0.014	0.014	0.166	1.000				
DCPVD	-0.261	-0.024	-0.162	-0.320*	-0.022	-0.066	0.271	0.304*	0.217	1.000			
RNFLT	-0.301*	-0.002	-0.235	-0.252	0.085	-0.004	0.318*	0.284	-0.017	0.234	1.000		
FMT	-0.182	-0.098	-0.202	-0.109	0.035	-0.057	0.154	0.165	-0.156	0.077	0.794**	1.000	
FAZ	0.078	0.203	0.138	-0.041	0.234	0.239	0.020	-0.055	0.271	0.039	-0.095	-0.362*	1.000

The "Duration" represents "Duration of SO tamponade"; "Follow-up time" represents the follow-up time after silicone oil removal surgery; "Detachment time" represents the interval between retinal detachment and surgery; SCPVD, DCPVD, and RNFLT are all values of the parafoveal area

SO silicone oil, BCVA best corrected visual acuity, FR fixation rate, MRS mean retinal sensitivity, SCP superficial capillary plexus, DCP deep capillary plexus, VD vascular density, RNFLT retinal nerve fiber layer thickness, FMT foveal macular thickness, FAZ foveal avascular zone

where \* represents  $P < 0.05$ ; \*\* represents  $P < 0.01$

**Table 4** Correlation analysis between values after silicone oil removal (Spearman method)

	Duration	Follow-up time	Detachment time	BCVA	2°FR	4°FR	2°MRS	6°MRS	SCPVD	DCPVD	RNFLT	FMT	FAZ
Duration	1.000												
Follow-up time	-0.330*	1.000											
Detachment time	0.660**	-0.520**	1.000										
BCVA	0.224	-0.024	0.095	1.000									
2°FR	-0.255	-0.003	-0.042	-0.091	1.000								
4°FR	-0.255	-0.051	-0.102	-0.038	0.913**	1.000							
2MRS	-0.480**	0.494**	-0.832**	-0.104	-0.055	-0.025	1.000						
6MRS	-0.601**	0.642**	-0.939**	-0.131	-0.031	0.024	0.904**	1.000					
SCPVD	-0.034	-0.287*	-0.027	-0.108	-0.030	0.118	0.027	-0.012	1.000				
DCPVD	-0.190	-0.108	-0.131	-0.310*	-0.122	-0.118	0.034	0.081	0.297*	1.000			
RNFLT	-0.296*	-0.091	-0.268	-0.108	-0.167	-0.072	0.265	0.264	0.289*	0.343*	1.000		
FMT	-0.187	-0.166	-0.155	0.082	-0.088	-0.154	0.094	0.064	-0.204	0.084	0.547**	1.000	
FAZ	-0.080	0.134	0.016	0.017	0.070	0.118	0.063	0.089	0.071	-0.180	-0.189	-0.548**	1.000

The "Duration" represents "Duration of SO tamponade"; "Follow-up time" represents the follow-up time after silicone oil removal surgery; "Detachment time" represents the interval between retinal detachment and surgery; SCPVD, DCPVD, and RNFLT are all values of the parafoveal area

BCVA best corrected visual acuity, FR fixation rate, MRS mean retinal sensitivity, SCP superficial capillary plexus, DCP deep capillary plexus, VD vascular density, RNFLT retinal nerve fiber layer thickness, FMT foveal macular thickness, FAZ foveal avascular zone

where \* represents  $P < 0.05$ , \*\* represents  $P < 0.01$

**Table 5** Correlation analysis between the increase of values after silicone oil removal (Spearman method)

	Duration	Follow-up time	Detachment time	BCVA	2°FR	4°FR	2°MRS all	6°MRS S	6°MRS I	SCPV D all	SCPV D S	SCPV DI	DCPV D all	DCPV D S	DCPVD I all	RNFLT S	RNFLT I	FMT	FAZ
Duration	1.000																		
Follow-up time	-0.330*	1.000																	
Detachment time	0.660**	-0.520**	1.000																
BCVA	0.038	0.170	0.048	1.000															
2°FR	-0.111	0.031	-0.045	-0.205	1.000														
4°FR	-0.168	0.064	-0.118	-0.149	0.904**	1.000													
2°MRS	0.302*	0.158	-0.141	-0.212	0.246	0.241	1.000												
all								0.342*	0.898**	1.000									
6°MRS	0.205	0.344*	-0.234	-0.037	0.344*	0.342*	0.898**	1.000											
all									0.836**	1.000									
6°MRS S	0.252	0.284	-0.140	0.085	0.284	0.283	0.727**	0.836**	1.000										
6°MRS I	0.137	0.313*	-0.248	-0.148	0.189	0.160	0.728**	0.815**	0.477**	1.000									
SCPVD	0.124	-0.232	0.046	0.237	0.236	0.194	0.077	0.058	0.013	-0.038	1.000								
all												0.949**	1.000						
SCPVD S	0.131	-0.317*	0.112	0.237	0.249	0.206	0.009	-0.027	-0.021	-0.143	0.949**	1.000							
SCPVD I	0.131	-0.162	0.032	0.227	0.125	0.104	0.105	0.095	0.010	0.058	0.930**	0.786**	1.000						
DCPVD	0.047	-0.028	-0.031	0.237	-0.162	-0.188	0.128	0.054	0.077	0.057	0.315*	0.292*	0.303*	1.000					
all															0.912**	1.000			
DCPVD S	0.115	-0.080	-0.004	0.227	-0.143	-0.184	0.136	0.046	0.125	0.027	0.289*	0.314*	0.223	0.912**	1.000				
DCPVD I	-0.008	0.065	-0.019	0.227	-0.183	-0.171	0.107	0.050	-0.014	0.074	0.234	0.146	0.298*	0.869**	0.646**	1.000			
RNFLT	0.128	-0.163	0.074	-0.195	-0.045	-0.032	0.079	0.094	0.035	0.143	-0.198	-0.219	-0.181	-0.174	-0.071	-0.180	1.000		
all																			
RNFLT S	0.162	-0.161	0.103	-0.169	-0.059	-0.058	0.054	0.084	0.080	0.093	-0.196	-0.223	-0.169	-0.196	-0.105	-0.202	0.965**	1.000	
RNFLT I	0.059	-0.084	-0.003	-0.174	-0.045	-0.010	0.127	0.142	-0.003	0.214	-0.155	-0.186	-0.141	-0.158	-0.071	-0.123	0.949**	0.846**	1.000
FMT	0.011	0.040	0.016	-0.195	-0.054	-0.036	0.086	0.144	0.165	0.129	-0.444**	-0.411**	-0.444**	-0.257	-0.187	-0.266	0.631**	0.630**	0.552*
FAZ	-0.075	-0.126	-0.062	0.037	-0.074	0.010	0.058	-0.062	-0.019	-0.033	-0.066	0.001	-0.133	0.004	0.043	-0.057	-0.021	0.006	-0.073

The "Duration" represents "Duration of SO tamponade"; "Follow-up time" represents the follow-up time after silicone oil removal surgery; "Detachment time" represents the interval between retinal detachment and surgery; SCPVD, DCPVD, and RNFLT are all values of the parafoveal area

BCVA best corrected visual acuity, FR fixation rate, MRS mean retinal sensitivity, SCP superficial capillary plexus, DCP deep capillary plexus, VD vascular density, RNFLT retinal nerve fiber layer thickness, S superior, I inferior, FMT foveal macular thickness, FAZ foveal avascular zone

where \* represents  $P < 0.05$ ; \*\* represents  $P < 0.01$

eyes with RRD. Complicated surgical procedures such as ILM peeling [17], stripping of the proliferative membrane, and photocoagulation were not included in this study. Third, phacoemulsification was performed prior to PPV or SO removal during both surgeries. Fourth, main outcome measures were acquired at least 3 months after SO removal. This period was sufficient for acute surgical inflammation and IOP fluctuations to subside. Through excluding the influence of surgical factors on retinal sensitivity and microcirculation, we aimed to isolate and evaluate the parameter changes due only to the SO.

In this study, we found that the degree of increase in BCVA, MRS, and FR were inconsistent after SO removal. SORVL alone cannot explain the damage to visual function caused by SO. In contrast to BCVA, statistical significance was observed in the changes in FR and MRS between before and 3 months after SO removal. Therefore, we suspect that the side effects of SO on FR and MRS are greater than those on BCVA, or that SORVL is more difficult to recover.

In addition, we found that MRS was affected by the duration of SO tamponade and the interval between retinal detachment and surgery in the state of SO tamponade and 3 months after SO removal, and recovered over time after SO removal. To date, the mechanisms underlying the side-effects of SO on retinal function remain unclear. Previous studies have found that retinal function in macula-off RRD eyes was lower than that in both contralateral eyes and eyes with macula-on RRD [18, 19]. Eshita et al. [20] performed scanning laser Doppler flowmetry to measure macular blood flow in 28 patients with macula-on RRD and found that the mean blood flow ratio in the RRD eye was lower than that in the contralateral eye, both pre- and post-operatively. Therefore, retinal ischemia at the detached areas in eyes with macula-on RRD was considered to reduce macular blood flow, which affects retinal function [18, 19].

According to the standard [10], one degree in microperimetry is equal to the length of a 250  $\mu\text{m}$  fundus. Correlations between 6° MRS, superior 6° MRS, inferior 6° MRS, and the corresponding parafoveal SCP VD, DCP VD, and RNFLT were tested before and after SO removal, but no correlations were observed 3 months after SO removal, which indicated that retinal microcirculation was not the only factor affecting retinal sensitivity. Another study showed that outer retinal layer damage in macula-off RRD was another factor affecting visual function [21]. Similarly, no correlations were found between their increase after SO removal, which indicated that retinal microcirculation was not the only factor in the side-effects of SO on retinal sensitivity. A previous study reported that the effect of SO on fixation stability and retinal sensitivity might be related to

xanthophyll pigment accumulation in the macula [22]. The interaction between lipophilic SO and pigment may also result in foveal damage, which explain the effects on fixation stability and retinal sensitivity.

Our study had some limitations. First, the retrospective single-center study design might have caused a selection bias. Second, the sample size was small and the follow-up periods were short. Third, many patients with long-term SO tamponade were excluded from this study because of poor image quality. Fourth, the effect of phacoemulsification and IOL implantation in the 10 eyes which underwent the procedure during SO removal could not be excluded. Finally, the relevant measurements of the RRD eyes before the first vitrectomy and the early period after SO tamponade were not included in the study.

## Conclusion

Retinal structure and function improved to different degrees after SO removal, and fixation stability and retinal sensitivity increased more than BCVA. Retinal sensitivity, which was affected by the interval between retinal detachment and surgery and the duration of SO tamponade, gradually recovered after SO removal.

## Abbreviations

SO	Silicone oil
RRD	Rhegmatogenous retinal detachment
BCVA	Best-corrected visual acuity
VD	Vessel density
RNFLT	Retinal nerve fiber layer thickness
FR	Fixation rate
MRS	Mean retinal sensitivity
SORVL	Silicone oil related vision loss
OCTA	Optical coherence tomography angiography
PPV	Pars plana vitrectomy
IOP	Intraocular pressure
ILM	Internal limiting membrane
SCP	Superficial capillary plexus
DCP	Deep capillary plexus
FMT	Foveal macular thickness
FAZ	Foveal avascular zone
MP-3	Microperimeter-3

## Acknowledgements

The authors thank Professor Yading Jia for his guidance and Miss Yan Li for coordination of research.

## Author contributions

RD wrote the main manuscript text. JJ and SC designed the study. RCL, YY, JZ, RML and XW collected and analyzed all data. RL performed the statistical analysis. JJ and DZ interpreted the data and results. All authors reviewed the manuscript.

## Funding

None.

## Availability of data and materials

The datasets generated during and/or analysed during the current study are available from the corresponding author on reasonable request.



## Declarations

### Ethics approval and consent to participate

This study was performed in accordance with the tenets of the Declaration of Helsinki and was approved by the Ethics Committee of Shanxi Aier Eye Hospital (EYESXY-20191008-01). All patients provided written informed consent to participate in this study.

### Consent for publication

No applicable.

### Competing interests

None of the authors have any proprietary interests or competing interests related to this submission.

### Author details

<sup>1</sup>Department of Ophthalmology, Qilu Hospital (Qingdao), Cheeloo College of Medicine, Shandong University, 758 Hefei Road, Qingdao 266035, China.

<sup>2</sup>Shanxi Aier Eye Hospital, Taiyuan 030000, Shanxi Province, China. <sup>3</sup>Clinical College of Ophthalmology, Tianjin Eye Hospital, Tianjin Medical University, No.4 Gansu Road, Heping District, Tianjin 300020, China.

Received: 10 November 2023 Accepted: 14 December 2023

Published online: 02 January 2024

## References

- Tomkins-Netzer O, Ismetova F, Bar A, Seguin-Greenstein S, Kramer M, Lightman S. Functional outcome of macular edema in different retinal disorders. *Prog Retin Eye Res.* 2015;48:119–36.
- Scheerlinck LM, Schellekens PA, Liem AT, Steijns D, van Leeuwen R. Retinal sensitivity following intraocular silicone oil and gas tamponade for rhegmatogenous retinal detachment. *Acta Ophthalmol.* 2018;96:641–7.
- Nagpal M, Khandelwal J, Eltayib A, Mehrotra N, Juneja R. Preoperative and postoperative macular sensitivity assessment using microperimetry in eyes undergoing silicone oil removal. *Retina.* 2020;40:1574–8.
- Jiang J, Chen S, Jia YD, Li R, Zhou JX, Li RM. Evaluation of macular vessel density changes after vitrectomy with silicone oil tamponade in patients with rhegmatogenous retinal detachment. *Int J Ophthalmol.* 2021;14:881–6.
- Jiang J, Li R, Zhou JX, Li RM, Wang RH, Wang XP, et al. Peripapillary changes after vitrectomy and silicone oil tamponade for rhegmatogenous retinal detachment. *Indian J Ophthalmol.* 2021;69:3579–83.
- Pfau M, Jolly JK, Wu Z, Denniss J, Lad EM, Guymer RH, et al. Fundus-controlled perimetry (microperimetry): application as outcome measure in clinical trials. *Prog Retin Eye Res.* 2021;82:100907.
- Csaky KG, Patel PJ, Sepah YJ, Birch DG, Do DV, Ip MS, et al. Microperimetry for geographic atrophy secondary to age-related macular degeneration. *Surv Ophthalmol.* 2019;64:353–64.
- Alonso-Plasencia M, Abreu-González R, Gómez-Culebras MA. Structure-function correlation using OCT angiography and microperimetry in diabetic retinopathy. *Clin Ophthalmol.* 2019;13:2181–8.
- Sharief L, Chen YH, Lightman S, Tomkins-Netzer O. Prospective study of morphologic and functional parameter changes post intravitreal therapy for macular edema. *Graefes Arch Clin Exp Ophthalmol.* 2020;258:1941–7.
- Wang Z, Qi Y, Liang X, Yu Y, Chen J, Wang J, et al. MP-3 measurement of retinal sensitivity in macular hole area and its predictive value on visual prognosis. *Int Ophthalmol.* 2019;39:1987–94.
- Liu Y, Wang Y, Dong Y, Liang D, Xie S, Xiao B, et al. Characteristics of fixation patterns and their relationship with visual function of patients with idiopathic macular holes after vitrectomy. *Sci Rep.* 2021;11:7658.
- Rossetti A, Doro D, Manfrè A, Midena E. Long-term follow-up with optical coherence tomography and microperimetry in eyes with metamorphopsia after macula-off retinal detachment repair. *Eye (Lond).* 2010;24:1808–13.
- Borowicz D, Nowomiejska K, Nowakowska D, Brzozowska A, Toro MD, Avitabile T, et al. Functional and morphological results of treatment of macula-on and macula-off rhegmatogenous retinal detachment with pars plana vitrectomy and sulfur hexafluoride gas tamponade. *BMC Ophthalmol.* 2019;19:118.
- Noda H, Kimura S, Hosokawa MM, Shiode Y, Doi S, Takahashi K, et al. Effect of rhegmatogenous retinal detachment on preoperative and postoperative retinal sensitivities. *Sci Rep.* 2020;10:21497.
- Scheerlinck LM, Kuiper JJ, Liem AT, Schellekens PA, van Leeuwen R. Electrolyte composition of retro-oil fluid and silicone oil-related visual loss. *Acta Ophthalmol.* 2016;94:449–53.
- Scheerlinck LM, Schellekens PA, Liem AT, Steijns D, van Leeuwen R. Incidence, risk factors and clinical characteristics of unexplained visual loss after intraocular silicone oil for macula-on retinal detachment. *Retina.* 2016;36:342–50.
- Eissa MGAM, Abdelhakim MASE, Macky TA, Khafagy MM, Mortada HA. Functional and structural outcomes of ILM peeling in uncomplicated macula-off RRD using microperimetry & en-face OCT. *Graefes Arch Clin Exp Ophthalmol.* 2018;256:249–57.
- Okamoto F, Sugiura Y, Okamoto Y, Hiraoka T, Oshika T. Changes in contrast sensitivity after surgery for macula-on rhegmatogenous retinal detachment. *Am J Ophthalmol.* 2013;156:667–72.
- Akiyama K, Fujinami K, Watanabe K, Noda T, Miyake Y, Tsunoda K. Macular dysfunction in patients with macula-on rhegmatogenous retinal detachments. *Br J Ophthalmol.* 2018;103:404–9.
- Eshita T, Shinoda K, Kimura I, Kitamura S, Ishida S, Inoue M, et al. Retinal blood flow in the macular area before and after scleral buckling procedures for rhegmatogenous retinal detachment without macular involvement. *Jpn J Ophthalmol.* 2004;48:358–63.
- Malosse L, Rousseau H, Baumann C, Angioi K, Leroy B, Sennlaub F, et al. Prevalence and risk factors for outer retinal layer damage after macula-off retinal detachment. *Br J Ophthalmol.* 2020;104:660–5.
- Balaratnasingam C, Chae B, Remmer MH, Gomez E, Suzuki M, Engelbert M, et al. The spatial profile of macular pigments is related to the topological characteristics of the foveal avascular zone. *Invest Ophthalmol Vis Sci.* 2015;56:7859–65.

## Publisher's Note

Springer Nature remains neutral with regard to jurisdictional claims in published maps and institutional affiliations.

### Ready to submit your research? Choose BMC and benefit from:

- fast, convenient online submission
- thorough peer review by experienced researchers in your field
- rapid publication on acceptance
- support for research data, including large and complex data types
- gold Open Access which fosters wider collaboration and increased citations
- maximum visibility for your research: over 100M website views per year

At BMC, research is always in progress.

Learn more [biomedcentral.com/submissions](https://biomedcentral.com/submissions)

